

1

Oral Soft Tissue Wound Healing

VIVEK SHETTY AND ANH D. LE

Definitions

A *wound*, regardless of the cause of injury, is a disruption of normal tissue continuity and integrity. *Healing* is simply the process of restoring the integrity of the wounded tissue. If the result is tissue that is structurally and functionally the same as the original tissue, then *regeneration* has taken place. However, if tissue integrity is reestablished primarily through the formation of a fibrous, connective-tissue scar, then *repair* has occurred. The nature of the native tissue involved determines whether regeneration or repair will ensue, and the surgeon's expectations should be correspondingly realistic. Whereas a fibrous scar may be normal for dermal healing, it is suboptimal in the case of bone healing.

General Considerations

Every injury initiates an orderly, but complex sequence of orchestrated events that reestablish the integrity of the damaged tissue. Despite the body's innate ability to heal, surgical intervention is often used to optimize the healing process and favorably modulate the outcome. Interventions may include adequate debridement of devitalized tissue, removal of diseased tissue or foreign materials, securing adequate hemostasis, and apposing severed tissues with mechanical means until such time the wound is capable of withstanding functional stresses.

From a surgical viewpoint, the nature of wound healing depends upon the site, type of tissue involved, and the surgeon's ability to approximate the wound margins. Healing by *first intention* usually occurs when early primary closure can be achieved by accurately reapproximating the wound margins. Such a wound heals quickly with no separation of the wound edges, and with minimal scar formation. Absent favorable conditions, wound healing is prolonged and occurs through a filling of the tissue defect with granulation and connective tissue. This process is called healing by *second intention* and is frequently encountered following avulsive injury, wound infection, or poor apposition of the wound margins. In instances of infected or contaminated traumatic wounds with severe tissue loss, the surgeon may attempt healing by *third intention*. This is a staged procedure wherein the wound is allowed to granulate and heal by second intention before a delayed primary closure is carried out by bringing together the two surfaces of granulation tissue.

Wound-Healing Phases

The healing process in different tissues occurs in a cascade of overlapping phases best represented by cutaneous wound healing. Beginning with the inflammatory phase precipitated by the injury, the wound eventually restores itself through sequentially occurring proliferative and remodeling phases. While the rates and patterns of healing depend on a host of local, systemic, and surgical factors, the phases of oral soft-tissue healing are typical for all other tissues as well. In general, wounds in the oral cavity seem to heal faster than wounds to the skin. Oral wounds, despite being exposed to a bacteria-laden, moist, seemingly hostile environment, heal perfectly well and reepithelialize rapidly with minimal or no scar formation.

Inflammatory Phase

The wounded area attempts to restore its normal state (homeostasis) immediately following injury. Disrupted blood vessels constrict and thrombose, and the thromboplastin released by the injured cells initiates the coagulation process. The accumulating platelets help form a fibrin clot to control bleeding. Additionally, the injured tissue and platelets begin to release key mediators of wound healing, particularly platelet-derived growth factors (PDGFs) and transforming growth factor β (TGF- β). These chemoattractants recruit inflammatory cells that begin to remove damaged tissue and bacteria from the injured area. Clinical signs include localized edema, pain, redness, and increased warmth at the wound site. Neutrophils are the predominant inflammatory cells during the initial 2 to 3 days following injury but are rapidly outnumbered by macrophages derived from mobilized monocytes. As the primary source of modulating cytokines such as PDGF and vascular endothelial growth factor (VEGF), the macrophages regulate the formation of the granulation tissue that is distinctive of the proliferation phase.¹

Proliferation Phase

The proliferation phase is a period of intense replication of cells and is characterized by the migration and proliferation of fibroblasts and smooth muscle cells into the wound milieu. The fibroblast is the major cell responsible for the production of collagen and proteoglycans. Fibroblasts interact with their surrounding matrix via receptors known as integrins that regulate the level of collagen gene expression and collagenase induction. Collagen restores the strength and integrity of the repaired tissue, whereas

the proteoglycans function as moisture storage. Concurrent with these events is the process of angiogenesis, whereby new blood vessels are formed and lymphatics are recanalized in the healing tissues. This essential process reestablishes transport of the nutrients and oxygen to the local injured site. In a synergistic way, the new capillaries supply nourishment to the developing collagen, while the collagen fibers structurally support the new capillary beds. Epithelial cells originating from hair follicles, sebaceous glands, and margins of the wound edges proliferate and resurface the wound above the basement membrane. In contrast to skin, the process of reepithelialization progresses more rapidly in the oral mucosal wound. The oral epithelial cells migrate directly onto the moist, exposed surface of the fibrin clot instead of under the dry exudate (scab) of the dermis as in dry skin.² The rapid reepithelialization limits further insults from the oral cavity environment such as food debris, foreign particles, and microorganisms.

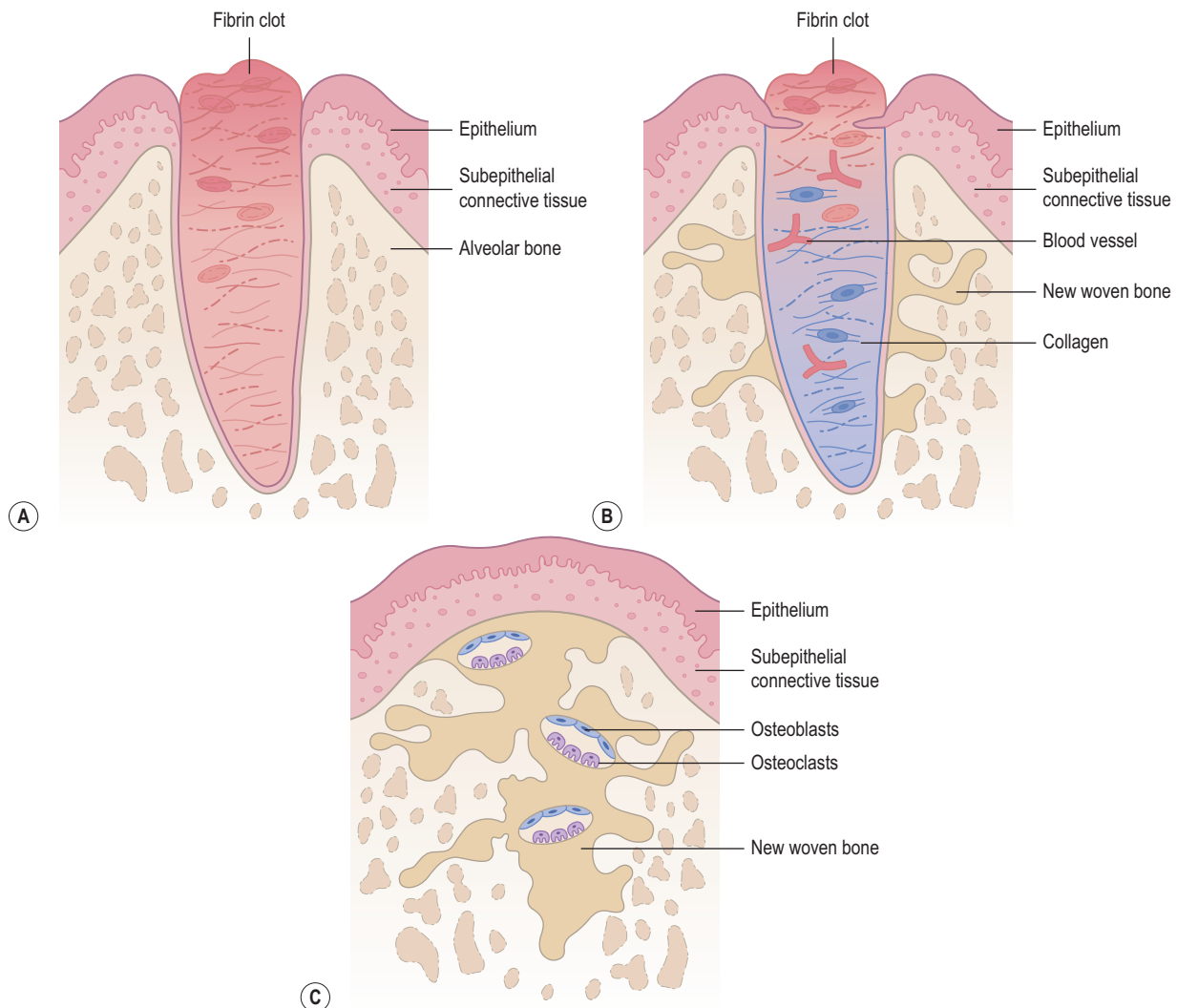
Maturation/Remodeling Phase

The remodeling phase is the final stage of tissue repair and is distinguished by a continual turnover of collagen molecules as precursor collagen is broken down and new collagen synthesized.

The tensile strength of the wound gradually restores as the collagen fibers are realigned and increasingly cross-linked to each other. The maximal tensile strength of a healed wound is reached in 6 to 12 months following injury but never reaches the strength of unwounded tissue. Eventually, active collagen synthesis achieves equilibrium with collagenolysis. However, disruptive processes such as poor oxygen perfusion, lack of nutrients, and wound infection can shift the balance to favor collagen breakdown and wound dehiscence.

Healing of Extraction Wounds

The healing of a dental extraction wound is a specialized example of healing by second intention (Fig. 1.1).³ Immediately after the removal of the tooth from the alveolus, blood fills the extraction site. Both intrinsic and extrinsic pathways of the clotting cascade are activated. The resultant fibrin meshwork containing entrapped red blood cells seals off the torn blood vessels and reduces the size of the extraction wound. Organization of the clot begins within the first 24 to 48 hours with engorgement and dilation of blood vessels within the periodontal ligament remnants, leukocytic migration, and formation of a fibrin layer. In the first week, the



• **Fig. 1.1** Healing of an extraction wound after: (A) 24–48 hours; (B) 1 week; (C) 2–4 weeks.

clot forms a temporary scaffold upon which inflammatory cells migrate. Epithelium at the wound periphery grows over the surface of the organizing clot. Osteoclasts accumulate along the alveolar bone crest (in humans) or margin (in animals) setting the stage for active crestal or marginal resorption. Angiogenesis begins in the remnants of the periodontal ligaments. In the second week, the clot continues to get organized through fibroplasia and neoangiogenesis that begin to penetrate toward the center of the clot. Trabeculae of osteoid slowly extend into the clot from the alveolus and osteoclastic resorption of the cortical margin of the alveolus is more distinct. By the third week, the extraction socket is filled with granulation tissue and poorly calcified bone forms around the periphery of the wound. The surface of the wound is completely reepithelialized with minimal or no scar formation. Active bone remodeling by deposition and resorption continues for several more weeks. Radiographic evidence of bone formation does not become apparent until 6 to 8 weeks following tooth extraction. As bone remodeling proceeds, the extraction site becomes less distinct and is inconspicuous after 6 to 8 months.

Rarely, the blood clot fails to form or may disintegrate, causing a localized alveolar osteitis. In such instances, healing is delayed considerably and the socket fills gradually. Because of the absence of a healthy granulation tissue matrix, the apposition of regenerate bone to remaining alveolar bone takes place at a much slower rate. Compared to a normal alveolus, the infected alveolus remains open or partially covered with hyperplastic epithelium for extended periods.

Factors Affecting Healing

Infection

Wound infection is the most common cause of impaired wound healing. Though oral wounds are always colonized by bacteria, infection occurs only when the virulence or the number of the bacteria exceeds the ability of local tissue and host defenses to control them. The likelihood of wound infection increases substantially when the bacteria proliferate to levels beyond 10^5 organisms per gram of tissue.⁴ Bacteria provoke various degrees of inflammation at the wounded tissue by releasing endotoxins, metalloproteinases, and breakdown products that inhibit the activities of regenerating cells and the scavenger macrophages. In addition to systemic diseases, local factors such as inadequate tissue perfusion and the presence of necrotic tissue or foreign bodies facilitate deterioration of a contaminated wound into an infected wound. The most important factor in minimizing the risk of infection is meticulous surgical technique, including thorough debridement, adequate hemostasis, and elimination of dead space. Proper postoperative care, including stringent wound hygiene and absence of reinjury, further reduces the risk of infection.

Tissue Perfusion and Oxygenation

Adequate tissue perfusion is critical to the healing process. To a certain degree, hypoxia stimulates the cells to produce angiogenic growth factors. However, severe tissue hypoxia combines with lactic acid produced by bacteria to lower tissue pH and contributes to tissue breakdown or necrosis.⁵⁻⁷ Wounds in hypoxic tissues are more easily infected and heal poorly as leukocytic, fibroblastic, and epithelial proliferation is depressed by low oxygen concentration. Poor oxygenation also interferes with the synthesis of collagen since oxygen is required for the hydroxylation of lysine and

proline.⁸ Furthermore, studies have shown that collagen deposition and wound tensile strength are limited by tissue perfusion and oxygen tension.⁹

The impaired healing associated with conditions such as diabetes mellitus, radiation damage, vasculitis, venous stasis, arteriosclerosis, and chronic infection can be largely ascribed to a faulty oxygen delivery system. Ischemic tissues produced by improper surgical techniques are poorly perfused and are excessively prone to infection. Tissue edema, remnants of necrotic tissues, or a systemic perfusion defect, such as hypovolemia, all impair wound healing. It follows that the natural resistance of the wound can also be enhanced by the maintenance of an adequate body fluid volume and satisfactory arterial oxygen tension. The use of hyperbaric oxygen to maintain the wound in a state of hyperoxia is based on this rationale.

Age

In general, oral wound healing is faster in the young animal than in the elderly. The influence of age on wound healing probably results from the general reduction of tissue metabolism that may be manifested by multiple physiologic problems as the animal ages. The major processes that drive soft-tissue healing are diminished or damaged with progressive age. As a result, free oxidative radicals continue to accumulate and are deleterious to the dermal enzymes responsible for the integrity of the dermal or mucosal composition. In addition, the regional vascular support may be subjected to extrinsic deterioration and systemic disease decompensation, resulting in poor perfusion capability.¹⁰

Diabetes Mellitus

Most of the complications related to diabetes, particularly poor wound healing, can be attributed to the development of diabetic microangiopathy. Local ischemia, secondary to poor oxygen delivery at the tissue level, and small vessel occlusion play an essential role in the pathogenesis and delayed healing of diabetes. Glycosylated hemoglobin has a higher binding affinity to oxygen molecules, which further impairs oxygen delivery to ischemic tissues. In addition, granulocyte function in uncontrolled diabetes is impaired, rendering animals with diabetes more susceptible to wound infection. Poor healing has also been related to the metabolic problems related to hyperglycemia, insulin deficiency, and/or insulin resistance. The wound in the diabetic animal often demonstrates a decreased inflammatory response, fibroblast proliferation, and collagen deposition, resulting in a healing product with reduced tensile strength. A stringent regulation of blood sugar is therefore essential in the diabetic patient undergoing surgery, to optimize the wound healing potential.

Malnutrition

Nutritional deficiencies that produce hypoproteinemia hinder wound healing and impair the immune defense by limiting the availability of the amino acids critical for the synthesis of collagen and other proteins. Methionine, in particular, is a key amino acid in wound healing. It is metabolized to cysteine and plays a vital role in the inflammatory, proliferative, and remodeling phases of wound healing. As long as a state of protein catabolism exists, the wound heals very slowly. Several vitamins and trace minerals play a significant role in wound healing. Vitamin C and iron are essential cofactors for the hydroxylation of lysine and proline

during collagen synthesis. Absent adequate compensatory collagen synthesis, scars may dissolve if collagenolytic activity continues unabated. Vitamin A is essential for normal immune function, epithelialization, and proteoglycan synthesis, and healing is impaired when vitamin A is deficient. The B-complex vitamins and cobalt are essential cofactors in the antibody formation, white blood cell function, and bacterial resistance. Vitamin D, thiamin, and riboflavin deficiencies also result in poor repair.

Copper is needed for lysyl amine oxidase, whereas calcium is required for the normal function of granulocyte collagenase and other collagenases at the wound site. Zinc deficiency retards both fibroplasia and reepithelialization.¹¹ Zinc is required for DNA replication and serves as a coenzyme for DNA-polymerase and reverse-transcriptase. However, pharmacologic overdosing of zinc levels can exert a distinctly detrimental effect on healing by inhibiting macrophage migration and interference with collagen cross-linking.

Current Trends in Wound Care

An increased understanding of the wound-healing processes has generated heightened interest in manipulating the wound micro-environment to facilitate healing. The traditional passive ways of treating wounds are rapidly giving way to approaches that actively modulate wound healing. These approaches include treatments that selectively jump-start the wound into the healing cascade, increase oxygenation and perfusion of the local tissues, or mechanically protect the wound.

Growth Factors

Growth factors and cytokines are essential regulators of the healing process and are found to be insufficiently present or dysfunctional in the non-healing wound. Over the years, a variety of topical exogenous recombinant growth factors have been investigated as agents to improve the wound-healing process. These include PDGF, angiogenesis factor, epidermal growth factor (EGF), transforming growth factor (TGF), fibroblast growth factor (bFGF), tumor necrosis factor (TNF), and interleukin-1 (IL-1). However, the potential of these extrinsic agents has not yet been realized clinically and may relate to figuring out which growth factors to put into the wound—and when and at what dose. To date, only a single recombinant growth factor—recombinant human platelet-derived growth factor-BB form or Becaplermin (Regranex gel; Smith & Nephew, Inc., Fort Worth, TX)—has been approved by the United States Food and Drug Administration for the treatment of cutaneous ulcers, specifically diabetic foot ulcers. The PDGF stimulates cellular growth and migration of granulation tissue, thereby promoting healing. However, Becaplermin is adjunctive to good wound care (GWC) practices, including good initial debridement and infection control. Results from several controlled human clinical trials show that platelet-derived growth factor-BB form gel was effective in healing lower extremity diabetic ulcers and significantly decreased their healing time when compared to the placebo group.^{12,13}

More recently, recombinant human keratinocyte growth factor 2 (KGF-2: Repifermin, Human Genome Sciences, Inc., Rockville, MD) has been shown to accelerate wound healing in experimental animal models. It enhances both the formation of granulation tissue in both young and old rabbits and wound closure of the human meshed skin graft explanted on athymic nude rats.^{14,15} The safety assessment of the drug showed that KGF-2 was well tolerated in human with no differences in adverse events.¹⁶

Topical chitosan, a derivative of chitin, is increasingly used in veterinary clinical medicine as a wound-healing accelerator for large open wounds. Chitosan appears to stimulate a rapid infiltration of inflammatory cells and granulation tissue formation along with an increased production of biological mediators and cytokines and fibroblastic proliferation.¹⁷ Typical complications associated with the application of large doses of chitosan (above 50 mg/kg) in dogs include leukocytosis, elevated serum LDH2, LDH3 isoenzymes, and severe hemorrhagic pneumonia.

Despite the promise and excitement, most of the growth factor studies to date have been small and have different endpoints and modes of administration. As such, all data related to exogenously growth factors should be interpreted with caution, and any off-label use of these products for the management of wounds should be used in conjunction with rigorous wound care, including operative debridement to remove impediments to healing.

Hyperbaric Oxygen Therapy

Hyperbaric oxygen therapy (HBOT) is occasionally used in veterinary medicine to raise tissue oxygen tension to a level that facilitates healing. In HBOT, 100% oxygen is delivered to the patient at pressures between 1.5 and 2.4 atmospheres. This stimulates the growth of fibroblasts and endothelial cells, increases the killing ability of leukocytes, and is lethal for anaerobic bacteria. Multiple studies in HBOT in the treatment of human diabetic patients suggest that HBOT can be an effective adjunct in the management of diabetic wounds.¹⁸ Animal studies suggest that HBOT could be beneficial in the treatment of osteomyelitis and soft tissue infections.^{19,20} Adverse effects of HBOT are barotrauma of the ear, seizure, and pulmonary oxygen toxicity.

Skin Substitutes

Immediate wound coverage is critical for the acceleration of wound healing. When the surface area is large, wounds can be covered by synthetic and natural dressings. The human skin substitutes available are grouped into three major types and serve as excellent alternatives to autografts. The first type consists of grafts of cultured epidermal cells with no dermal components (Epicel; Genzyme Tissue Repair Corp., Cambridge, MA). The second type has only dermal components (AlloDerm Regenerative Tissue Matrix; LifeCell Corp., Woodlands, TX; Dermagraft; Advanced BioHealing, Inc., La Jolla, CA). The third type consists of a bilayer of both dermal and epidermal elements (Apligraf; Organogenesis Inc., Canton, MA; Integra; Johnson & Johnson Medical Integra Life Sciences Corp., Plainsboro, NJ). The chief effect of most skin substitutes is to promote wound healing by stimulating the recipient host to produce a variety of wound-healing cytokines. The use of cultured skin to cover wounds is particularly attractive inasmuch as the living cells already know how to produce growth factors at the right time and in the right amounts.

References

1. Singer AJ, Clark RA. Cutaneous wound healing. *N Engl J Med.* 1999;341:738–746.
2. Gustafson GT. Ecology of wound healing in the oral cavity. *Scand J Haematol Suppl.* 1984;40:393–409.
3. Huebsch RF, Hansen LS. A histopathologic study of extraction wounds in dogs. *Oral Surg Oral Med Oral Pathol.* 1969;28:187–196.

4. Robson MC, Krizek TK, Heggers JP. Biology of surgical infection. In: Ravitch MM, ed. *Current Problems in Surgery*. Chicago, IL: Yearbook Medical Publishers; 1973:1–62.
5. Hunt TK, Conolly WB, Aronson SB, Goldstein P. Anaerobic metabolism and wound healing: a hypothesis for the initiation and cessation of collagen synthesis in wounds. *Am J Surg*. 1978; 135:328–332.
6. Knighton DR, Silver LA, Hunt TK. Regulation of wound-healing angiogenesis effect of oxygen gradients and inspired oxygen concentration. *Surgery*. 1981;90:262–270.
7. LaVan FB, Hunt TK. Oxygen and wound healing. *Clin Plast Surg*. 1990;17:463–472.
8. Chvapil M, Hurych J, Ehrlichova E. The influence of varying oxygen tensions upon proline hydroxylation and the metabolism of collagenous and non-collagenous proteins in skin slices. *Hoppe Seylers Z Physiol Chem*. 1968;349:211–217.
9. Jonsson K, Jensen JA, Goodson WH III, et al. Tissue oxygenation, anemia, and perfusion in relation to wound healing in surgical patients. *Ann Surg*. 1991;214:605–613.
10. Fenske NA, Lober CW. Structural and functional changes of normal aging skin. *J Am Acad Dermatol*. 1986;15:571–585.
11. Tengrup I, Ahonen J, Zederfeldt B. Granulation tissue formation in zinc-treated rats. *Acta Chir Scand*. 1980;146:1–4.
12. Steed DL. Clinical evaluation of recombinant human platelet-derived growth factor for the treatment of lower extremity diabetic ulcers. Diabetic Ulcer Study Group. *J Vasc Surg*. 1995; 21:71–81.
13. Wieman TJ, Smiell JM, Su Y. Efficacy and safety of a topical gel formulation of recombinant human platelet-derived growth factor-BB (Becaplermin) in patients with non healing diabetic ulcers: a phase III, randomized, placebo-controlled, double-blind study. *Diabetes Care*. 1998;21:822–827.
14. Xia YP, Zhao Y, Marcus J, et al. Effects of keratinocyte growth factor-2 (KGF-2) on wound healing in an ischemia-impaired rabbit ear model and on scar formation. *J Pathol*. 1999;188:431–438.
15. Soler PM, Wright TE, Smith PD, et al. In vivo characterization of keratinocyte growth factor-2 as a potential wound healing agent. *Wound Repair Regen*. 1999;7:172–178.
16. Robson MC, Phillips TJ, Falanga V, et al. Randomized trial of topically applied repifermin (recombinant human keratinocyte growth factor-2) to accelerate wound healing in venous ulcers. *Wound Repair Regen*. 2001;9:347–352.
17. Ueno H, Murakami M, Okumura M, Kadosawa T, Uede T, Fujinaga T. Chitosan accelerates the production of osteopontin from polymorphonuclear leukocytes. *Biomaterials*. 2001;22:1667–1673.
18. Faglia E, Favales F, Aldeghi A, et al. Adjunctive systemic hyperbaric oxygen therapy in the treatment of severe prevaletly ischemic diabetic foot ulcers. A randomized study. *Diabetes Care*. 1996;19:1338–1343.
19. Mader JT, Guckian JC, Glass DL, Reinartz JA. Therapy with hyperbaric oxygen for experimental osteomyelitis due to *Staphylococcus aureus* in rabbits. *J Infect Dis*. 1978;138:312–318.
20. Bakker DJ. Selected aerobic and anaerobic soft tissue infections. In: Kindwall EP, Whelan HT, eds. *Hyperbaric Medicine Practice*. 2nd ed. Flagstaff, AZ: Best Publishing Company; 1999:575–601.

Abstract: Wound healing is a complex and dynamic biological process that involves many cell types and mediators interacting in a highly orchestrated temporal sequence to replace and restore devitalized and missing cellular structures and tissues. Although most healing culminates uneventfully, a variety of intrinsic and extrinsic factors can impede or facilitate the process. Understanding wound

healing at multiple levels—biochemical, physiologic, cellular, and molecular—provides the veterinarian with a framework for surgical approaches and judicious use of exogenous biologics for optimizing the healing response.

Keywords: absolute versus relative stability; direct and indirect bone healing; strain; vascular supply.