

Sinus Aspergilloma

A CASE REPORT

ASPERGILLOSIS

ASPERGILLOSIS = fungal disease, it exists in two forms: a **noninvasive** form and an **invasive** form (SECOND IN FREQUENCY ONLY TO CANDIDIASIS)

Noninvasive = affects the normal host appearing as an allergic reaction or a cluster of fungal hyphae (**fungal ball**)

Invasive = affects the immunocompromised patient (AIDS, SOLID ORGAN TRANSPLANTATION, UNCONTROLLED DIABETES)

ASPERGILLOSIS

ASPERGILLOSIS = fungal disease = SPORES reside worldwide in soil, water or decaying organic debris.
Released into the air and inhaled by human host

**Two most common species are
A. FLAVUS and A. FUMIGATUS**

CLINICAL MANIFESTATION

DEPENDING ON THE HOST IMMUNE STATUS AND PRESENCE OF TISSUE DAMAGE

Noninvasive

Allergic reaction: allergic fungal sinusitis attack due to the inhalation of the spores

Fungal ball: sometimes a low grade infection established in the sinus resulting in a mass of fungal hyphae called **ASPERGILLOMA**

CLINICAL MANIFESTATION

DEPENDING ON THE HOST IMMUNE STATUS AND PRESENCE OF TISSUE DAMAGE

Invasive

immunocompromised patients susceptible to oral aspergillosis, portal of entry the marginal gingiva or endodontic treatment or tooth extraction especially in the posterior treatment.

locally: painful gingival ulceration = swelling and violaceous hue = if not treated necrosis.

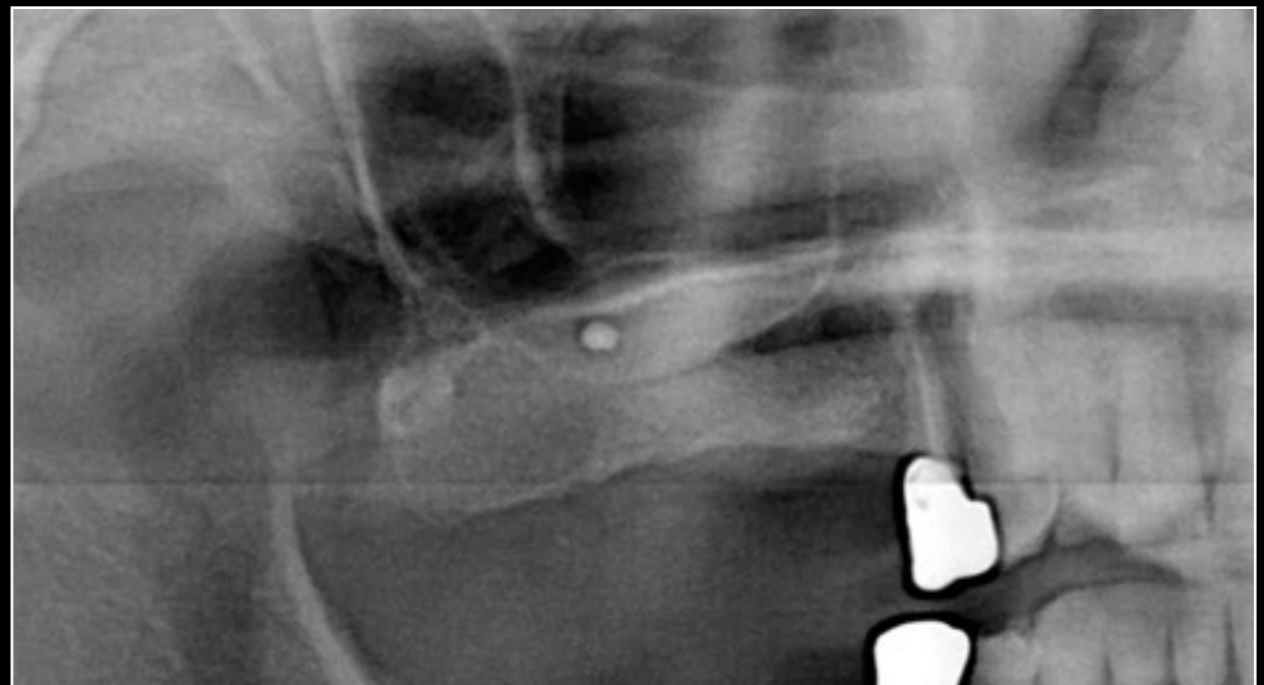
Disseminated aspergillosis (leukemia or high doses of corticosteroids)
chest pain fever = vague symptoms = difficult diagnosis, if the infection gains the blood CNS, liver, thyroid damage.

DEFINITION

FUNGAL BALL or ASPERGILLOMA are extramucosal collections of fungal elements, usually localized to a single sinus cavity, commonly the maxillary sinus. They are usually of the noninvasive variety, and commonly seen in immunocompetent hosts. Occasionally a waning of the immunity can cause them to turn invasive.

DEFINITION

Occasionally, the mass will undergo dystrophic calcification (radiopaque body) called **ANTROLITH**



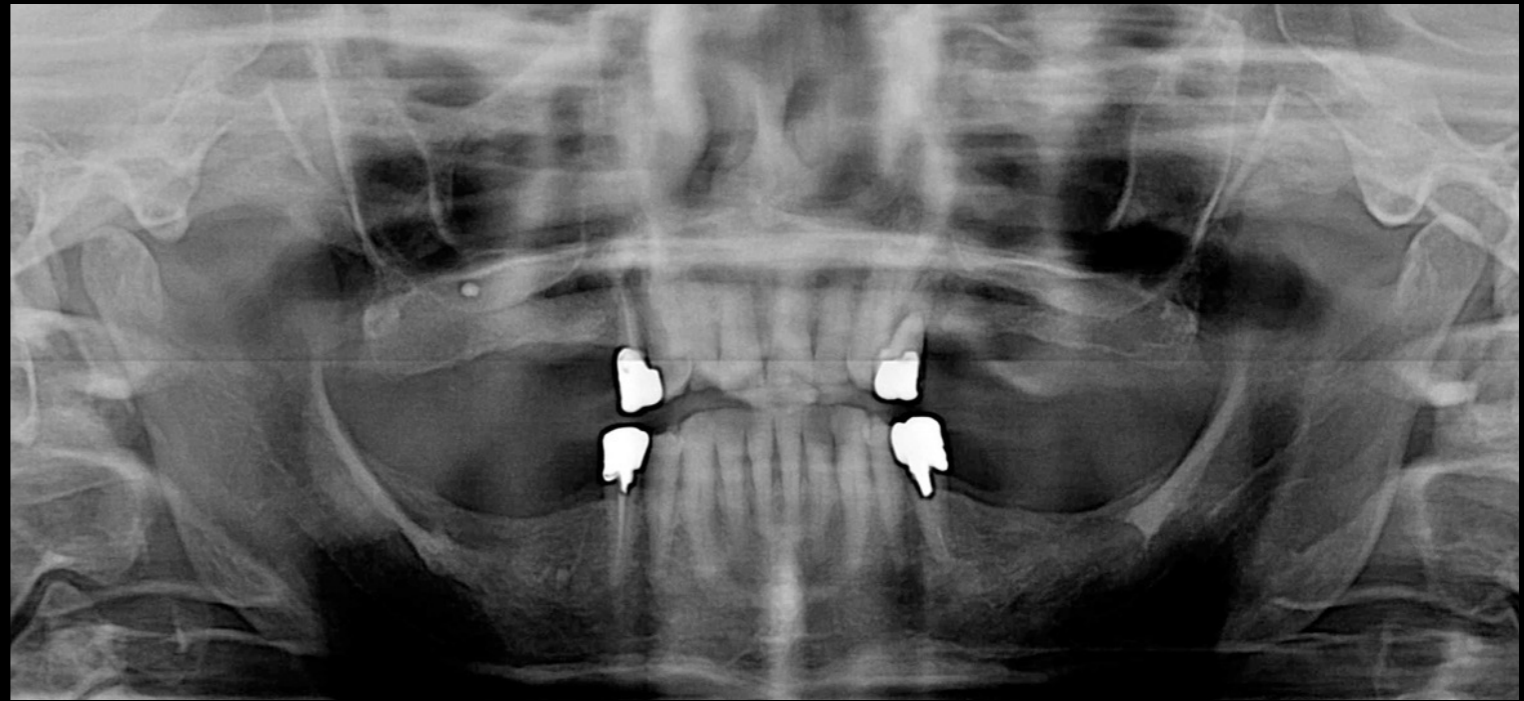
CASE HISTORY

CASE HISTORY

Female patient 76 years old.
Type II diabetes (no drugs)

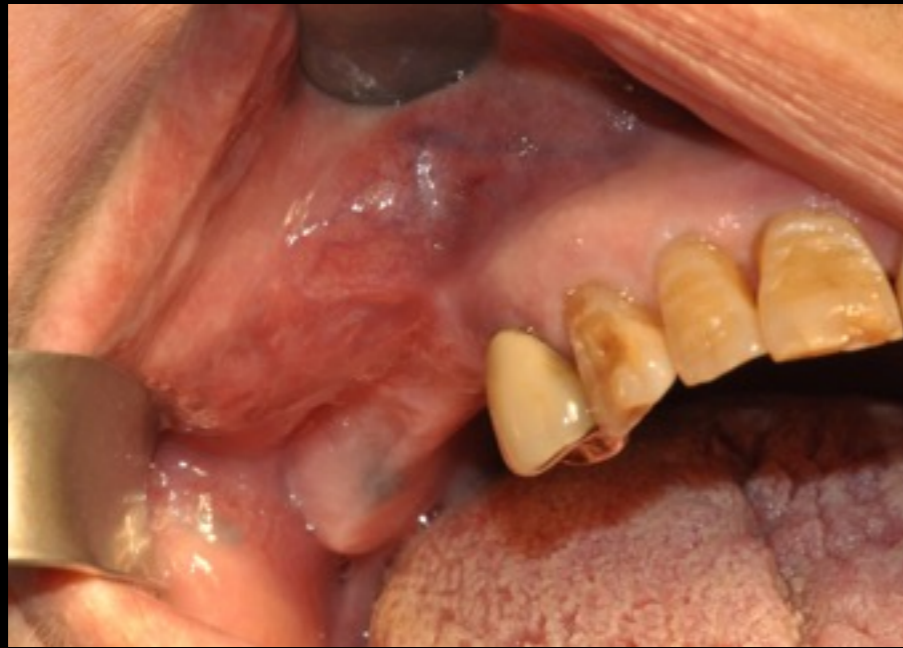The patient came to our observation
because of a trauma.
During a routine rx OPT we saw a
mass in the right maxillary sinus

A high resolution TC has been asked
for the investigation.

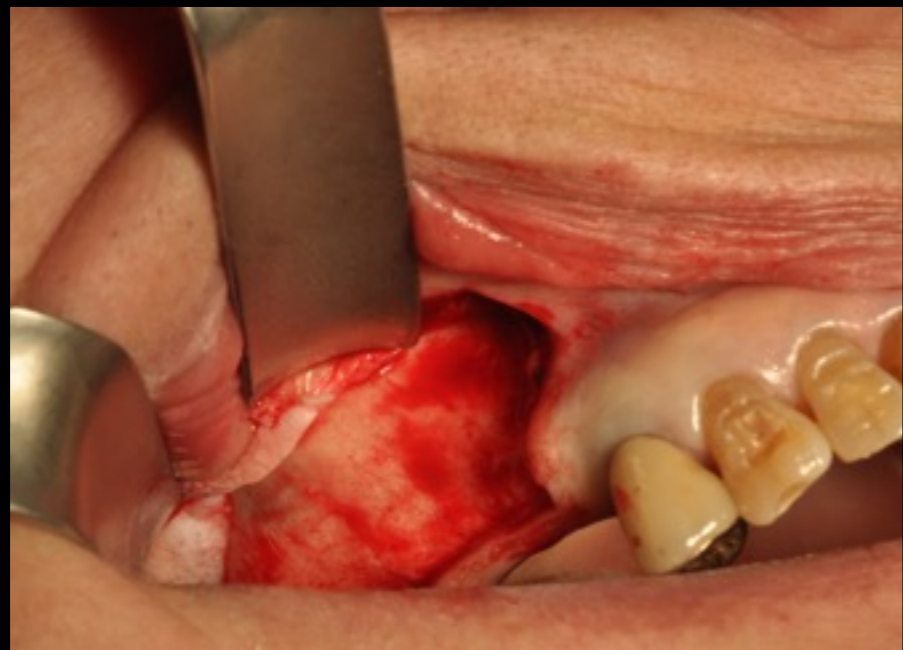

Patient underwent surgery to remove the lesion compatible with suspected aspergilloma

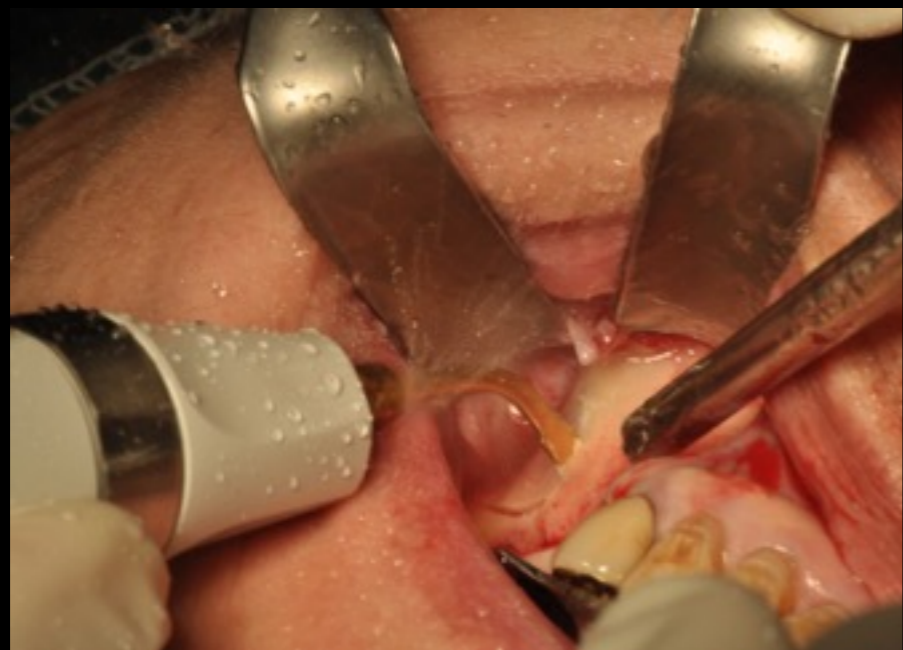
1



2

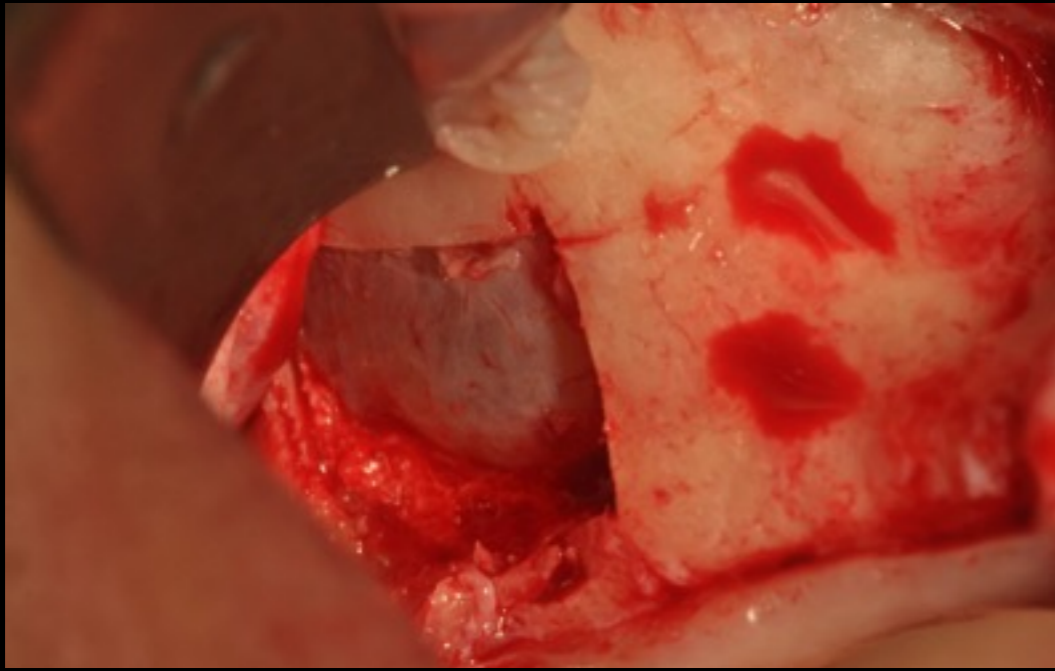


3



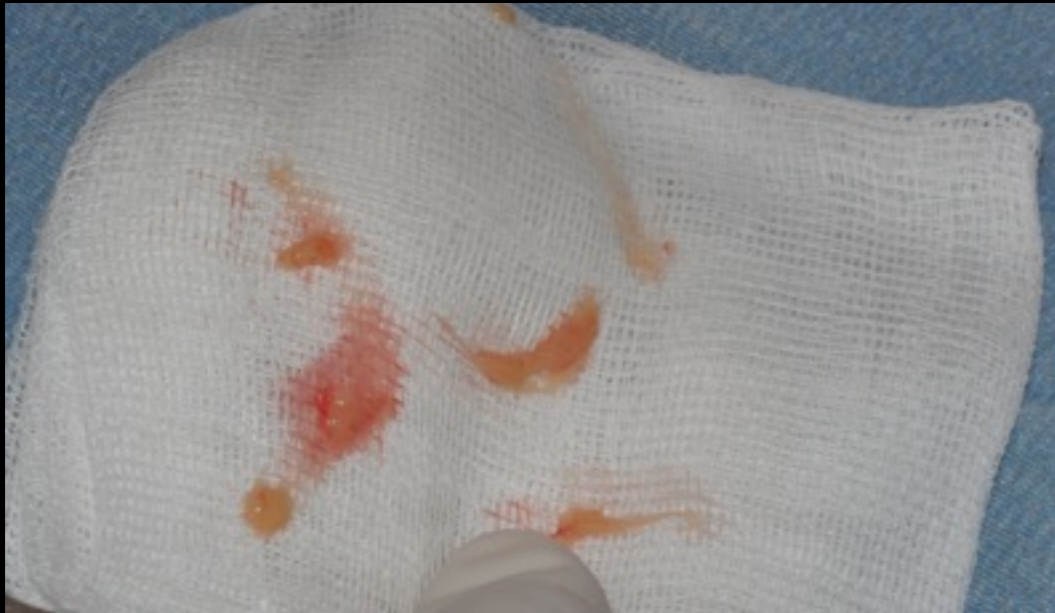Allestimento botola ossea a mezzo inserti piezoelettrici. Individuazione membrana di Schneider e accesso al seno mascellare destro mediante interruzione della stessa.

4

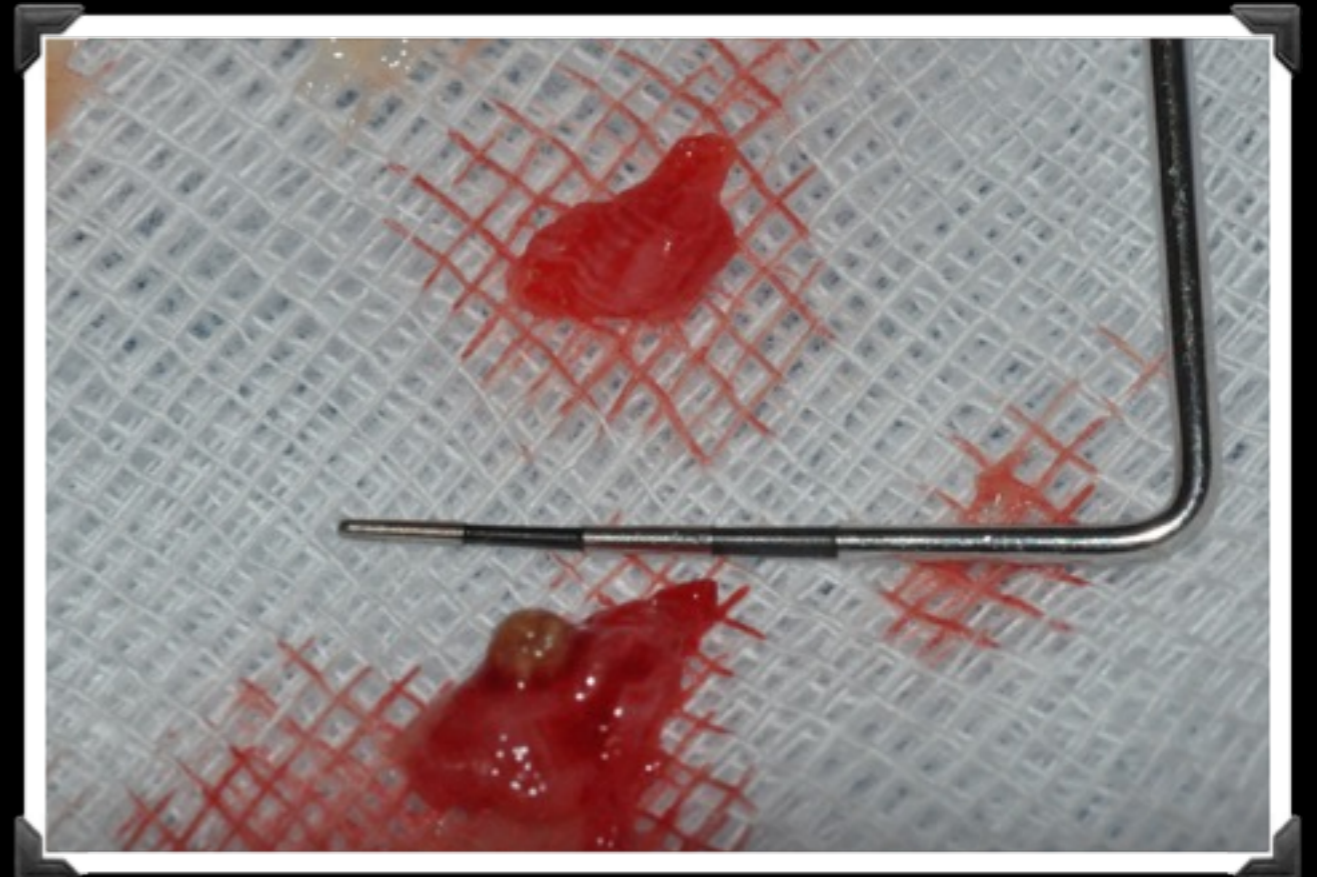
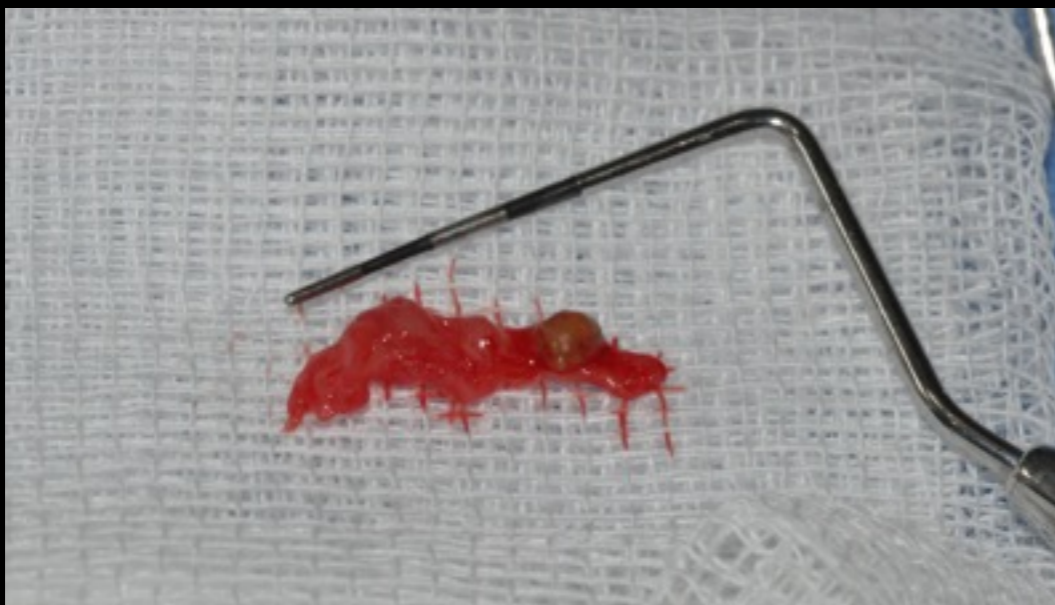

Ispezione con fibroscopio con sonda flessibile. Drenaggio ascesso seno mascellare e rimozione corpo estraneo compatibile con sospetta aspergillosi.

5

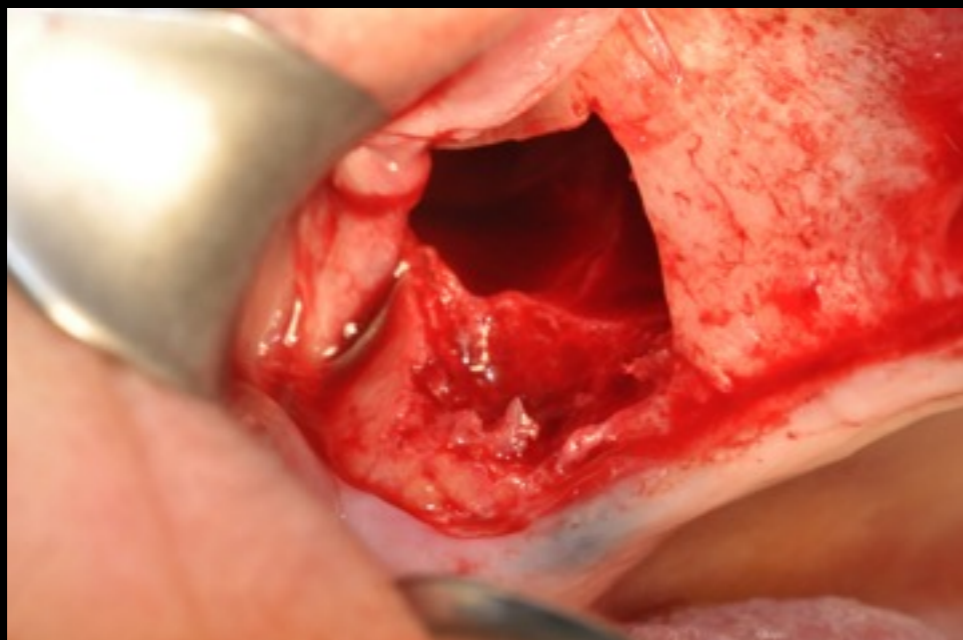

6

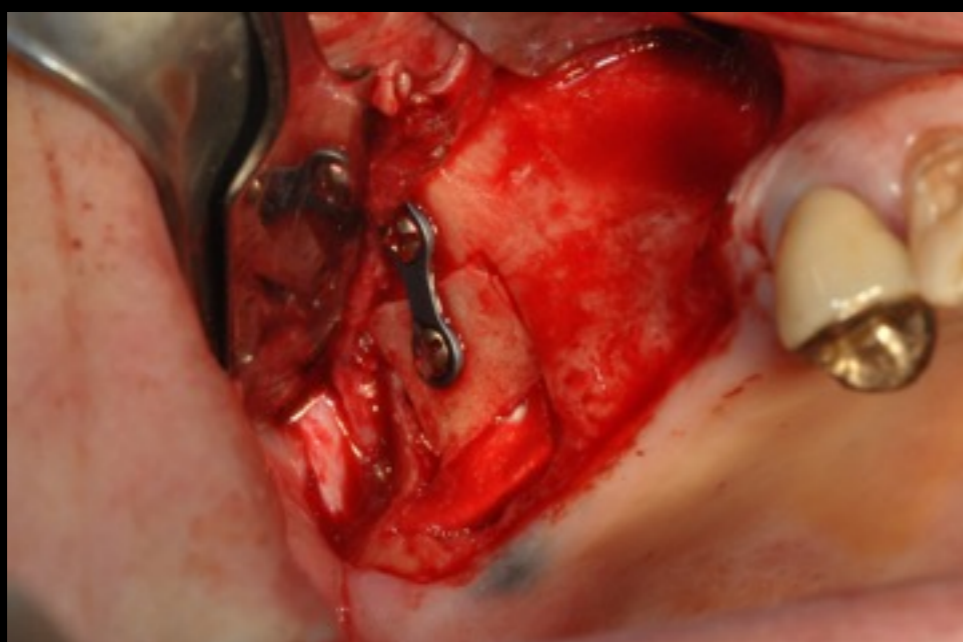


Curettage e detersione seno mascellare.

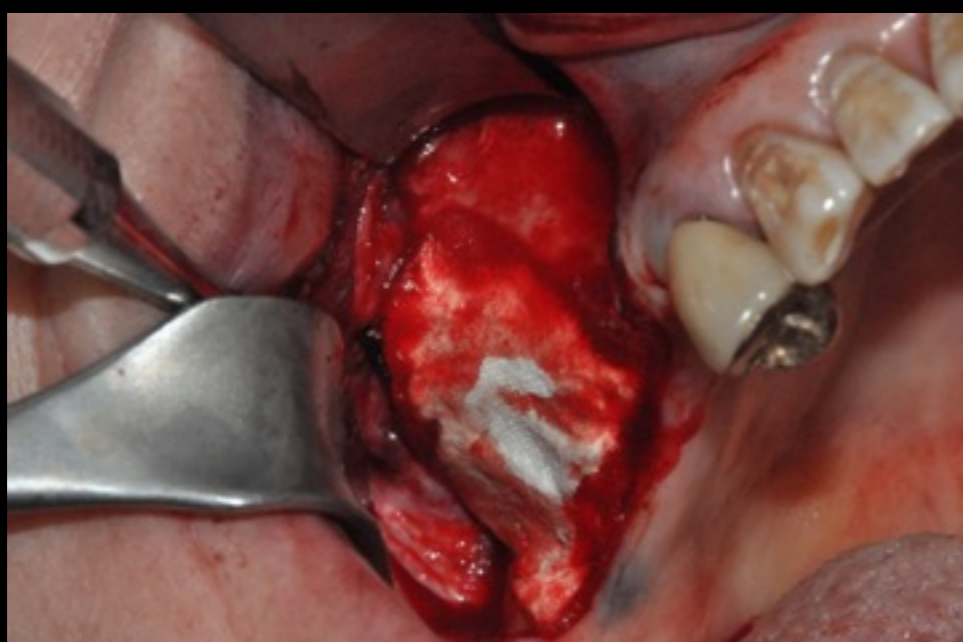
7



8

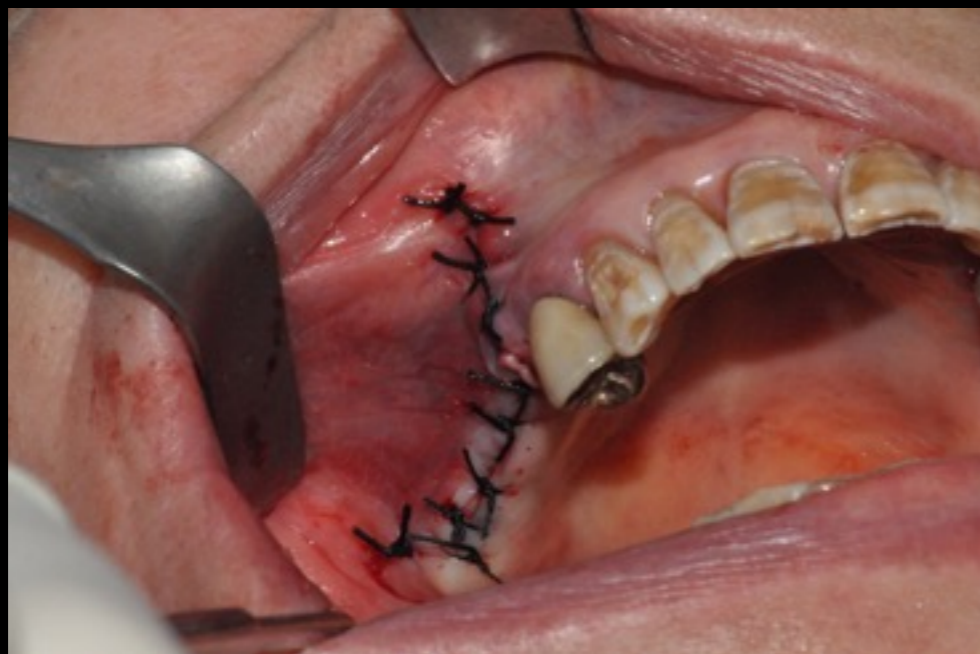

9



Riposizionamento botola ossea a mezzo viti e placche di osteosintesi. Chiusura porzione rimanente del difetto con membrana in collagene riassorbibile. Protezione di botola ossea a mezzo membrana in collagene riassorbibile. Sutura per prima intenzione.

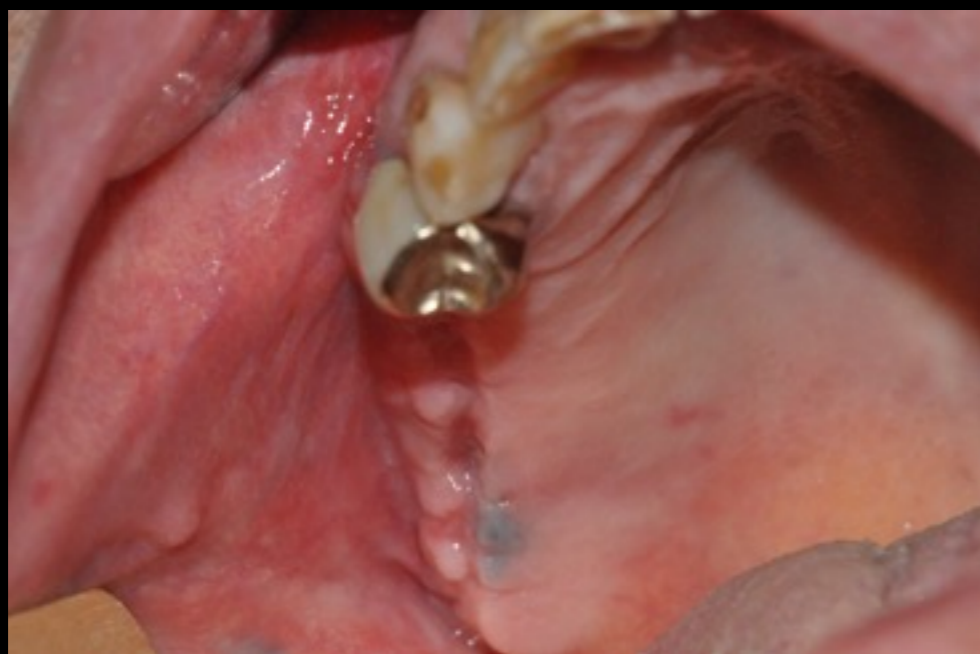10



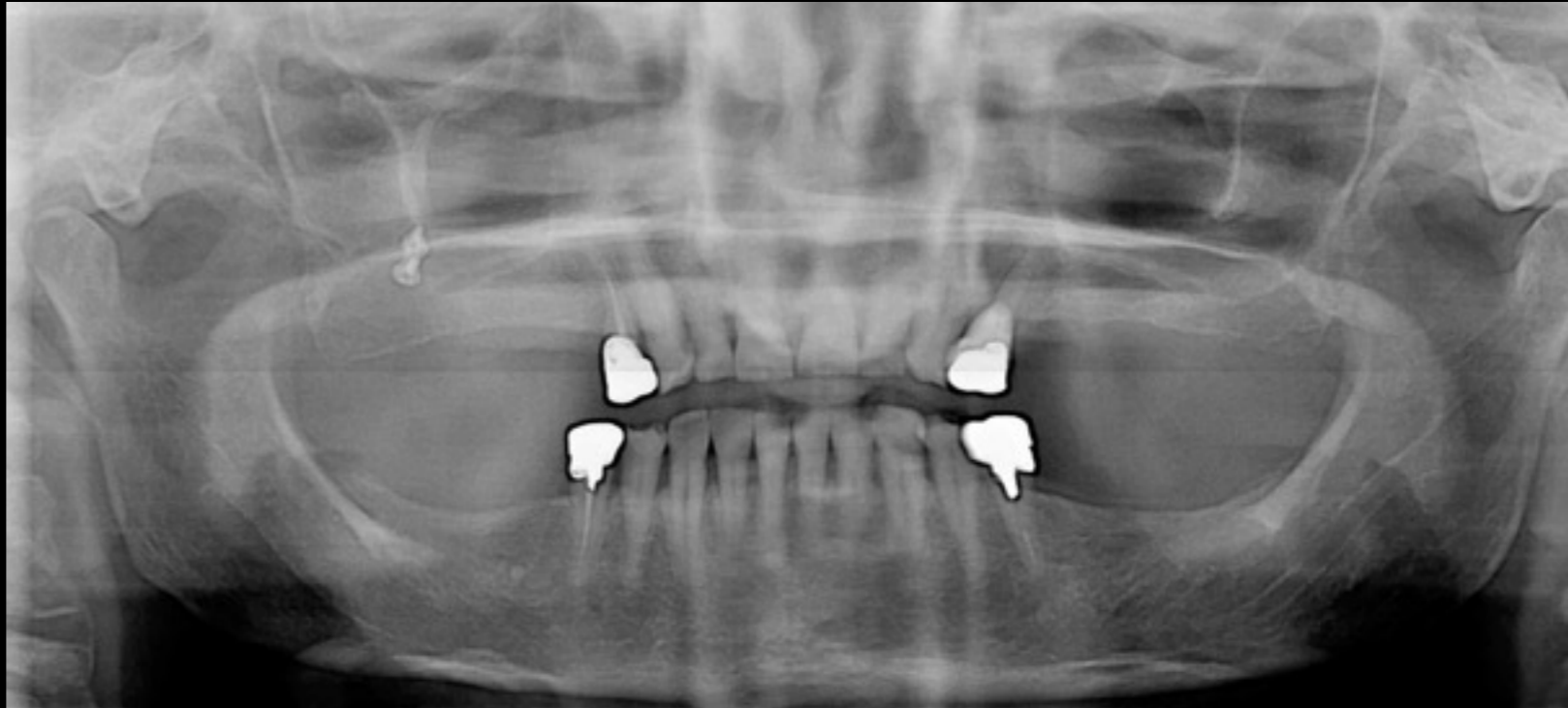
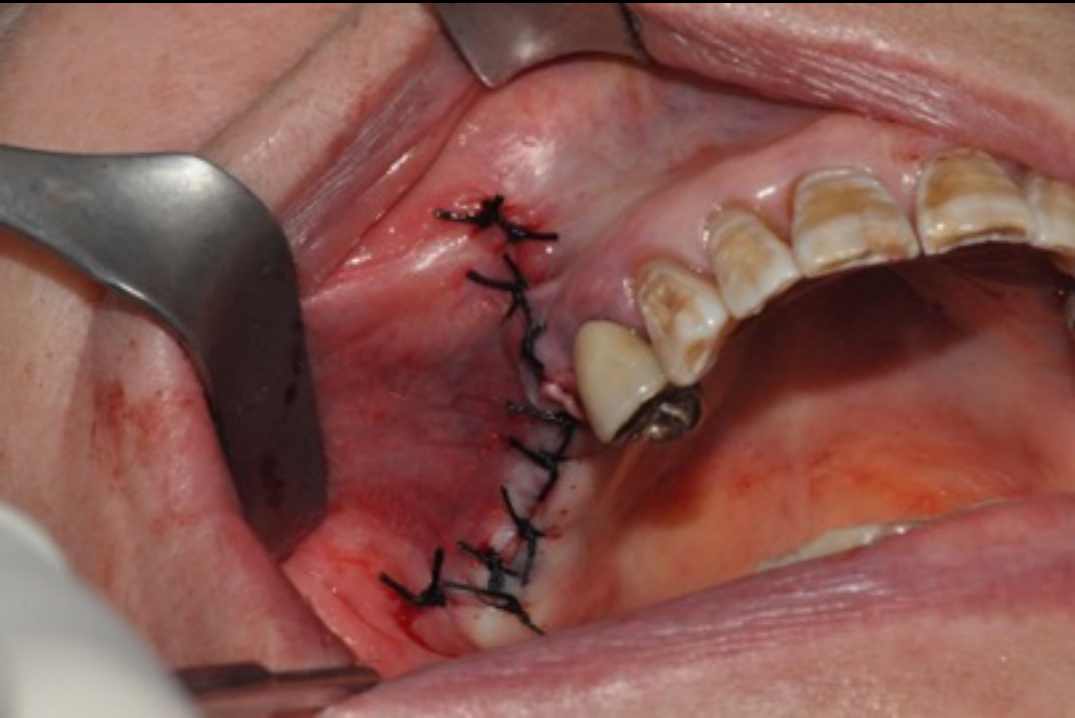Sutura per prima intenzione.

Consegnata terapia Ab con Amoxicillina 1 g da assumere 3/die per una settimana, antidolorifico al bisogno

11



Rimozione suture e controllo ad una settimana



HISTOPATOLOGIC

noninvasive form are features that differ from invasive

ASPERGILLOMA is characterized by tangle mass of hyphae with no evidence of tissue invasion and present large pool of eosinophilic inspissated mucin and lymphocytes

INVASIVE FORM: the hyphae branch in an acute angle, invade small blood vessel = occlusion = necrosis

MANAGEMENT

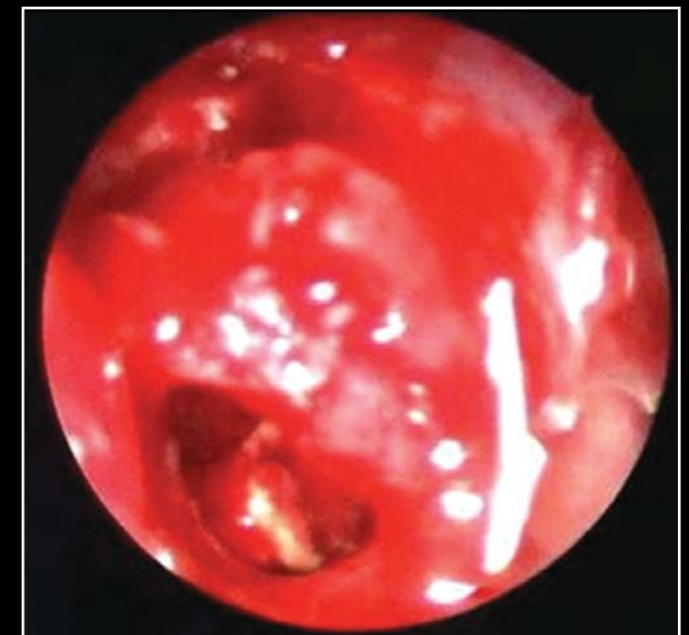The goal of treatment for a fungus ball (**immunocompetent patient with low kind of aspergillosis**) is surgical removal of the hyphal mass with re-establishing the drainage from the affected sinus + corticosteroid.

Endoscopic sinus surgery to remove the fungus ball is the treatment of choice

Irrigation of the sinus is performed to clear the sinus of all the fungal debris.

Recurrence is rare but, has been reported to occur even as late as two years following surgery

A regular follow-up is important as many of these recurrences can be addressed with simple irrigation or suctioning in the outpatient department or conservative endoscopic surgery



MANAGEMENT

For the **immunocompetent patient with invasive aspergillosis** : surgical removal + antifungal medication (voriconazole a triazole antifungal)

For the **immunocompromised patient with invasive aspergillosis** : aggressive surgical removal + systemic antifungal therapy (triazole antifungal)
only one third of this patient survive (usually develops while hospitalized)